



## Thyroid chondroplasty: Smoothing the thyroid cartilage— A retrospective study of thyroid chondroplasty for feminine neck appearance

Noga Lipschitz <sup>a</sup>, Michael Wolf<sup>a,b</sup>, Ofer Amir<sup>c</sup>, Doron Sagiv<sup>a</sup>, and Adi Primov-Fever<sup>a,b</sup>

<sup>a</sup>Department of Otolaryngology and Head and Neck Surgery, Sheba Medical Center, Tel Hashomer, Israel; <sup>b</sup>Sackler Faculty of Medicine, Tel Aviv University, Tel Aviv, Israel; <sup>c</sup>Department of Communication Disorders, The Stanley Steyer School of Health Professions, Sackler Faculty of Medicine, Tel-Aviv University, Tel Aviv, Israel

### ABSTRACT

**Background:** Thyroid chondroplasty is a surgical intervention for reduction of the Adam's apple, performed in trans women to achieve a more feminine appearance of the neck. This procedure is necessary since hormonal therapy given as part of gender affirming medical interventions has no effect on the mature larynx.

**Objectives:** We aim to describe our thyroid chondroplasty surgical technique and outcome of all thyroid chondroplasties performed during the study period.

**Methods:** A retrospective chart review of all thyroid chondroplasty procedures performed in a tertiary referral center between 2006 and 2015. Patients' clinical characteristics and surgical outcome were recorded and analyzed.

**Results:** Twenty-seven trans women underwent thyroid chondroplasty in our institution. Post-operative complications included a single patient who suffered from false vocal fold (ventricular folds) hematoma that resolved spontaneously. Five other patients had an erythematous scar. No other complications were observed.

**Conclusion:** Thyroid chondroplasty is a safe procedure for achieving a feminine neck contour in trans women.

### KEYWORDS

Adam's apple; chondroplasty; neck; thyroid cartilage

### Introduction



Trans women may choose to undergo medical and surgical treatment as part of their transition. Hormonal therapy influences skin and hair texture as well as breasts growth; however, exogenous female hormones have no effect on the laryngeal framework or voice characteristics in adults (Kanagalingam et al., 2005; Davies, Papp, & Antoni, 2015).

The laryngeal prominence (i.e., Adam's apple) is more protruded in males. Classically, this is attributed to a narrower angle between the thyroid laminae in males compared to females (Eckel, Sittel, Zorowka, & Jerke, 1994). In addition, clinical observations demonstrate that the laryngeal prominence is influenced not only by the inter-laminae angle, but also by the anterior projection of the superior part of the thyroid ala, which is more apparent in males and creates a bulging prominence (Sagiv et al., 2016). These gender-related anatomic differences occur during puberty, and prior

to puberty the laryngeal framework is similar or near similar between males and females (Glikson, Sagiv, Eyal, Wolf, & Primov-Fever, 2017).

Gender affirming medical procedures can address this anatomic difference, in a procedure also known as thyroid chondroplasty, thyroid cartilage reduction, or thyroid shave. Moreover, many trans women desire a surgical intervention for raising their voice pitch. This can be achieved by the approximation of the cricoid and thyroid cartilages in Isshiki type-4 procedure, i.e., cricothyroid approximation (Friedrich, de Jong, Mahieu, Benninger, & Isshiki, 2001; Spiegel, 2006). Yet, this procedure causes an anterior–inferior rotation of the larynx, and further accentuates the protrusion of the Adam's apple.

Thyroid chondroplasty is the surgical procedure aimed to improve the appearance of the neck in trans women. First described by Wolfort and Parry (1975), thyroid chondroplasty involves resection of the

**CONTACT** Noga Lipschitz  [Noga.Lipschitz@sheba.health.gov.il](mailto:Noga.Lipschitz@sheba.health.gov.il)  Department of Otolaryngology and Head and Neck Surgery, Sheba Medical Center, Tel Hashomer, Ramat Gan 5262100, Israel.

Color versions of one or more of the figures in the article can be found online at [www.tandfonline.com/wijt](http://www.tandfonline.com/wijt).

© 2017 Taylor & Francis Group, LLC

anterior–superior segment of the thyroid cartilage. The thyroid and cricoid cartilages comprise the outer laryngeal framework, and house the vocal folds and other soft tissue components that take part in voice production and airway protection. Within the larynx, the vocal folds meet medially at the anterior commissure, which attaches to the inner surface of the thyroid cartilage in the midline, at approximately halfway of the cartilage's vertical height (Eckel, Sittel, Zorowka, & Jerke, 1994). Thus, the extent of the cartilage resection in thyroid chondroplasty is limited by the vocal folds' attachment, in order to preserve their structure and function. Additionally, age-related calcification of the thyroid cartilage (Glikson, Sagiv, Eyal, Wolf, & Primov-Fever, 2017) might add a technical difficulty to the chondroplasty. A number of techniques have been described for cartilage resection, including the use of rongeurs (Wolfort & Parry, 1975; Wolfort, Dejerine, Ramos, Parry, & Edgerton, 1990), blade (Giraldo, Grado, & Montes, 1997), cartilage cutting forceps (Al-Jassim & Lesser, 2006), scissors (Kanagalingam et al., 2005), and a fissure burr (Matai, Cheesman, & Clarke, 2003). In this article, we aim to describe our thyroid chondroplasty surgical technique and outcome.

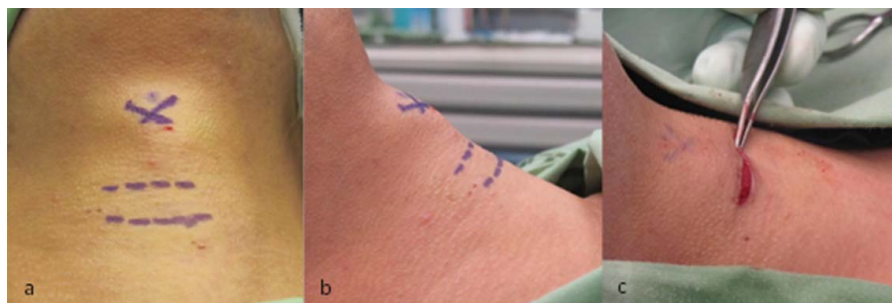
### Materials and methods

A retrospective chart review of all thyroid chondroplasty procedures performed in Sheba Medical Center, a tertiary referral center in Israel between 2006 and 2015. The medical records were reviewed for patients' demographic and clinical characteristics, surgical details and outcome. The surgical technique is described in details. The study was approved by the institutional ethics committee (No. SMC-12-9959).

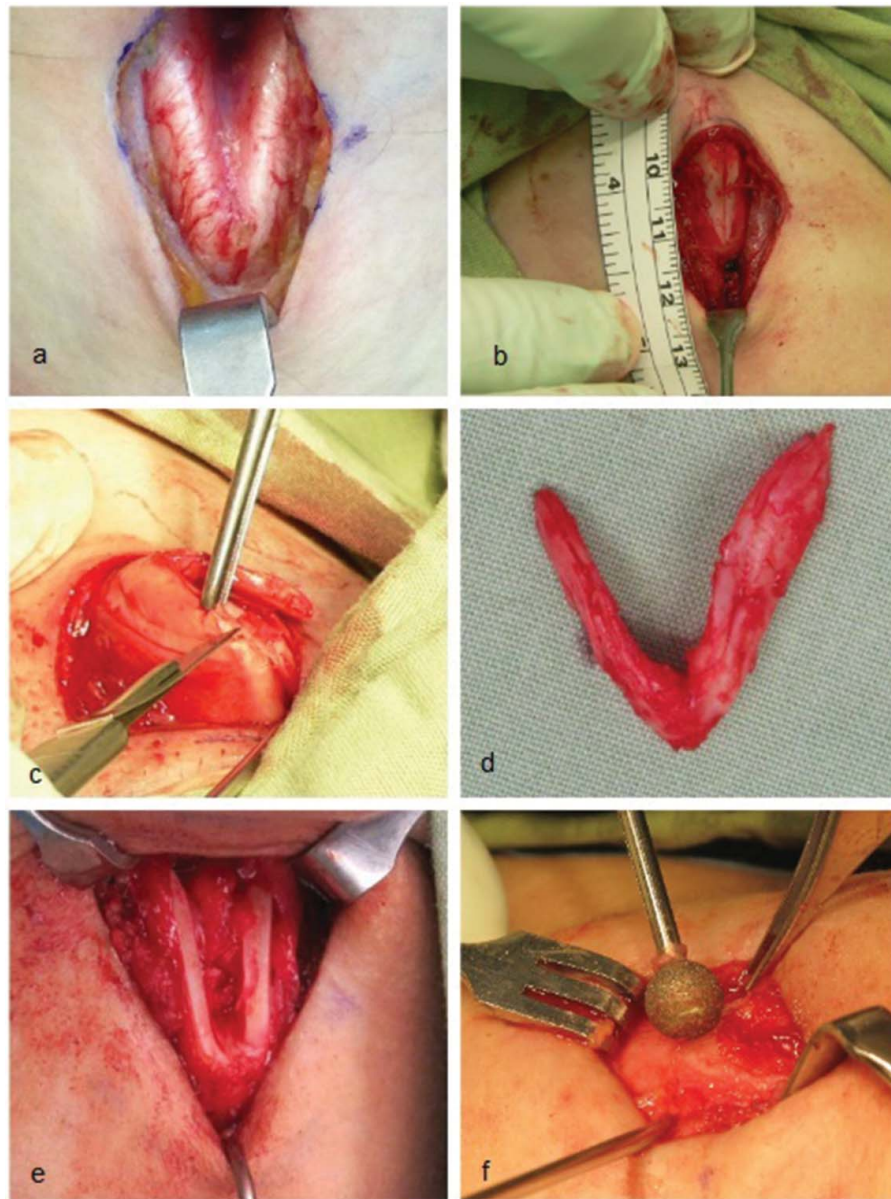
## Results

### Surgical technique

Under general anesthesia, a 2-cm transverse skin incision is performed halfway between the thyroid and the cricoid cartilages, preferably over a natural skin crease (Figure 1). This incision provides a wide exposure of both the thyroid and cricoid cartilages and is preferred in patients undergoing simultaneous thyroid chondroplasty and cricothyroid approximation. In patients undergoing thyroid chondroplasty alone, the skin incision can be performed higher in the neck (in the submental area) as exposure of the thyroid cartilage only is needed. The strap muscles are retracted laterally to expose the thyroid cartilage (Figure 2a). The vertical midline length of the cartilage is measured (Figure 2b), and marked halfway to denote the level of the vocal folds. An incision is made over the rim of the thyroid ala and the perichondrium is separated from the inner and outer surfaces of the cartilage superior part, down to the petiole of the epiglottis, nearly 1–2 mm above the level of the vocal folds (Figure 2c). A strip of cartilage is excised, including the thyroid notch and superior ala bilaterally (Figure 2d), staying above the marked vocal fold level. The cartilage's cut edges are examined and smoothed with a diamond burr (Figure 2e). Then, the anterior thyroid angle is thinned and refined with a diamond burr, to achieve a more rounded shape (Figure 2f). The perichondrium is repositioned and sutured over each side of the remaining thyroid ala. The strap muscles are approximated back in the midline. The skin is closed in two layers with absorbable sutures, and a fine drain is left for 24 hours. Figure 3 shows the neck appearance with a healed scar post-operatively.



**Figure 1.** Incision planning for thyroid chondroplasty. A transverse skin incision is made halfway between the thyroid and the cricoid cartilages. The X marks the thyroid notch, the lower line marks the cricoid cartilage and the middle line marks the planned incision site. a and b: incision planning; c: incision in previously marked middle line location.



**Figure 2.** Illustration of the major operative steps in thyroid chondroplasty [a] thyroid cartilage exposure, [b] the vertical midline length of the cartilage is measured, and marked half-way to denote the level of the vocal folds, [c] separation of the thyroid cartilage's inner and outer perichondrium, [d] excised thyroid cartilage segment, [e] thyroid cartilage cut edge, [f] smoothing the cut edge and refining the anterior prominence using a diamond burr.

In one patient with an ossified thyroid cartilage, a sagittal micro-saw blade was used to remove the superior part of the ossified thyroid ala.

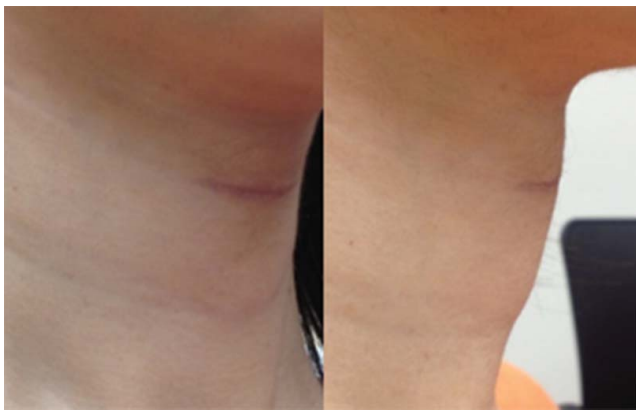### Patients

During the study period, 27 patients underwent thyroid chondroplasty using the technique described. Mean age at surgery was 30.63 years (range 23–43). Five patients underwent genital affirmation surgery prior to chondroplasty, three additional patients have

undergone genital affirmation surgery following chondroplasty and the remaining 19 patients have not undergone genital affirmation surgery. However, 13 patients had prior other gender affirmation surgeries, including rhinoplasty, breast augmentation, liposuction, cranioplasty and mandibular osteotomy. Of the 27 patients, 15 also underwent simultaneous cricothyroid approximation to achieve a higher pitch voice. Mean post-operative follow-up was 2.71 months.

One patient suffered from false vocal fold hematoma that resolved completely following a few days of



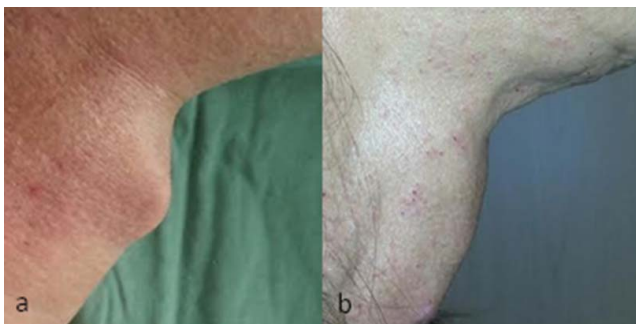

**Figure 3.** Neck appearance with a healed scar post-operatively.

observation. An erythematous scar was observed in five patients. No other complications were detected. **Figure 4** shows the neck contour before (a) and after (b) thyroid chondroplasty.

## Discussion

Thyroid chondroplasty is one of several gender affirmation surgeries offered to trans women. The World Professional Association for Transgender Health (WPATH) Standards of Care, 7th Version, 2011 (Coleman et al., 2012) include thyroid chondroplasty among the surgical procedures offered to trans women. While eligibility criteria are given for chest reconstructive surgery and genital affirmation surgery, no criterion is given for non-genital, non-breast surgical interventions, a category that includes facial feminization surgery and thyroid chondroplasty (Wesp & Deutsch, 2017). While traditionally considered an aesthetic procedure, thyroid chondroplasty is now regarded as an important component of gender affirmation surgery. Previous studies have shown that facial feminization surgery can improve quality of life



**Figure 4.** A patient before (a) and after (b) thyroid chondroplasty.

and relieve gender dysphoria in transgender individuals (Ainsworth & Spiegel, 2010; Berli et al., 2017a, b; Raffaini, Magri, & Agostini, 2016). Moreover, the WPATH standards of care, 7th Version state that facial feminization surgery can be considered medically necessary in cases of severe gender dysphoria. One study showed that the interest in facial feminization surgery among trans women was similar to interest in genital surgery (Kailas, Lu, Rothman, & Safer, 2017). This may have important implications on insurance coverage (Berli et al., 2017a,b; Wesp & Deutsch, 2017;), making thyroid chondroplasty available to more patients.

Each patient in our series underwent different sets of gender affirmation procedures at a different sequence. This in fact mirrors the reality of many (if not most) trans women, and highlights the importance of a patient centered model of care (Wesp & Deutsch, 2017). Many trans women will seek hormonal or surgical intervention, though not all, and there is a variation in the extent of intervention desired by each patient. Hence, each trans woman may undergo different interventions at a different order depending on numerous factors, including not just patient wishes but also insurance coverage, financial ability, and the level of psychosocial and educational care available to guide and support these decisions (Wesp & Deutsch, 2017).

The purpose of thyroid chondroplasty is reshaping the thyroid cartilage, to achieve a more feminine appearance without harming the laryngeal structure and function. Most previous publications state that males exhibit a thyroid inter-laminae right angle of approximately  $90^\circ$ , while females exhibit an obtuse angle of approximately  $120^\circ$  (Eckel, Sittel, Zorowka, & Jerke, 1994). A recent radiographic study showed that this angle is even more acute in males, and that the thyroid cartilage's anterior projection is more prominent in males than in females (Sagiv et al., 2016), adding to difference in neck appearance between genders. It should be clarified that thyroid chondroplasty surgery does not modify the inter-laminae angle, but only reduces the anterior projection of the thyroid laminae, by resecting the superior–anterior segment of the cartilage. However, the extent of cartilage resection is limited by the anterior attachment of the vocal folds to the thyroid cartilage. This is essential to avoid damage to the endo-larynx, and specifically to the vocal folds. One patient in our series experienced false vocal

fold hematoma that resolved completely within a few days. It is possible to perform intra-operative laryngoscopy using a rigid or flexible endoscope in order to verify the vocal folds' location during excision of the cartilage. It is our opinion that performing appropriate intra-operative measurements of the cartilage height and excising only the upper part of the cartilage are sufficient to avoid potential injury to the vocal folds, thus not necessitating additional intra-operative endoscopy with its associated operative time and costs. This however should be left to the surgeon's discretion, and may be used routinely or in chosen cases.

In addition to these considerations, calcification of the thyroid cartilage with advanced age might necessitate the use of alternative instruments to excise the harder, ossified cartilage (Al-Jassim & Lesser, 2006; Kanagalingam et al., 2005; Wolfort, Dejerine, Ramos, Parry, & Edgerton, 1990). In our series, the need for a micro-saw blade was encountered only once. This may be attributable to the relatively younger age of our patients (mean 30.2 years) compared to previous publications (Al-Jassim & Lesser, 2006; Kanagalingam et al., 2005; Matai, Cheesman, & Clarke, 2003), which could be related to the fact that a full governmental support for the process is provided in our country, including pitch-raising phono-surgery and thyroid chondroplasty.

The limitations of our study include the small number of patients, and the lack of subjective and objective outcome measures. To our knowledge, there are currently no objective measures available for evaluating the post-operative outcome of thyroid chondroplasty, and this should be the focus of future studies.

## Conclusion

Our study highlights the advantages of thyroid chondroplasty in trans women, providing feminization of the neck contour with minimal morbidity. Further research should provide new measures (objective and subjective) for quantifying post-operative outcome.

## Declaration of conflict of interest/ethical approval

All procedures performed in studies involving human participants were in accordance with the ethical standards of the institutional and/or national research committee and with the 1964 Helsinki declaration and its later amendments or comparable ethical standards. For this type of study, formal consent is not required.

## ORCID

Noga Lipschitz  <http://orcid.org/0000-0002-1252-8641>

## References

- Ainsworth, T. A., & Spiegel, J. H. (2010). Quality of life of individuals with and without facial feminization surgery or gender reassignment surgery. *Quality of Life Research*, 19(7), 1019–1024. doi: 10.1007/s11136-010-9668-7
- Al-Jassim, A. H., & Lesser, T. H. (2006). Reduction of Adam's apple for appearance. *Indian Journal of Otolaryngology and Head & Neck Surgery*, 58(2), 172–173. doi:10.1007/BF03050778
- Berli, J. U., Capitan, L., Simon, D., Bluebond-Langner, R., Plemons, & Morrison, S. D. (2017a). Facial gender confirmation surgery – review of the literature and recommendations for version 8 of the WPATH standards of care. *International Journal of Transgenderism*, 18(3), 241–247.
- Berli, J. U., Knudson, G., Fraser, L., Tangpricha, V., Ettner, R., Ettner, F. M., ... Schechter, L. (2017b). What surgeons need to know about gender confirmation surgery when providing care for transgender individuals: A review. *JAMA Surgery*, 152(4), 394–400. doi: 10.1001/jamasurg.2016.5549
- Coleman, E., Bockting, W., Botzer, M., Cohen-Kettenis, P., DeCuypere, G., Feldman, J., ... Zucker, K. (2012). Standards of care for the health of transsexual, transgender, and gender nonconforming people, 7th version. *International Journal of Transgenderism*, 13(4), 165–232.
- Davies, S., Papp, V. G., & Antoni, C. (2015). Voice and communication change for gender nonconforming individuals: Giving voice to the person inside. *International Journal of Transgenderism*, 16(3), 117–159.
- Eckel, H.E., Sittel, C., Zorowka, P., & Jerke, A. (1994). Dimensions of the laryngeal framework in adults. *Surgical and Radiologic Anatomy*, 16(1), 31–36.
- Friedrich, G., de Jong, F. I., Mahieu, H. F., Benninger, M. S., & Isshiki, N. (2001). Laryngeal framework surgery: A proposal for classification and nomenclature by the Phonosurgery Committee of the European Laryngological Society. *European Archives of Oto-Rhino-Laryngology*, 258(8), 389–396.
- Giraldo, F., Grado, J., & Montes, J. (1997). Aesthetic reductive thyroid chondroplasty. *International Journal of Oral and Maxillofacial Surgery*, 26(1), 20–22.
- Glikson, E., Sagiv, D., Eyal, A., Wolf, M., & Primov-Fever, A. (2017). The anatomical evolution of the thyroid cartilage from childhood to adulthood: A computed tomography evaluation. *Laryngoscope*. Advance online publication. doi: 10.1002/lary.26644
- Kailas, M., Lu, H. M. S., Rothman, E. F., & Safer, J. D. (2017). Prevalence and types of gender affirming surgery among a sample of transgender endocrinology patients prior to state expansion of insurance coverage. *Endocrine Practice*, 23(7), 780–786. doi: 10.4158/EP161727.OR
- Kanagalingam, J., Georgalas, C., Wood, G. R., Ahluwalia, S., Sandhu, G., & Cheesman, A. D. (2005). Cricothyroid

- approximation and subluxation in 21 male-to-female transsexuals. *Laryngoscope*, 115(4), 611–618.
- Matai, V., Cheesman, A. D., & Clarke, P. M. (2003). Cricothyroid approximation and thyroid chondroplasty: A patient survey. *Otolaryngology–Head and Neck Surgery*, 128(6), 841–847.
- Raffaini, M., Magri, A.S., & Agostini, T. (2016). Full facial feminization surgery: Patient satisfaction assessment based on 180 procedures involving 33 consecutive patients. *Plastic and Reconstructive Surgery*, 137(2), 438–448. doi: 10.1097/01.prs.0000475754.71333.f6
- Sagiv, D., Eyal, A., Mansour, J., Nakache, G., Wolf, M., & Primov-Fever, A. (2016). Novel anatomic characteristics of the laryngeal framework: A computed tomography evaluation. *Otolaryngology–Head and Neck Surgery*, 154(4), 674–678. doi: 10.1177/0194599815627781
- Spiegel, J. H. (2006). Phonosurgery for pitch alteration: Feminization and masculinization of the voice. *Otolaryngologic Clinics of North America*, 39(1), 77–86.
- Wesp, L. M., & Deutsch, M. B. (2017). Hormonal and surgical treatment options for transgender women and transfeminine spectrum persons. *Psychiatric Clinics of North America*, 40(1), 99–111. doi: 10.1016/j.psc.2016.10.006
- Wolfort, F. G., Dejerine, E. S., Ramos, D. J., Parry, R. G., & Edgerton, M. T. (1990). Chondrolaryngoplasty for appearance. *Plastic and Reconstructive Surgery*, 86(3), 464–469.
- Wolfort, F. G., & Parry, R. G. (1975). Laryngeal chondroplasty for appearance. *Plastic and Reconstructive Surgery*, 56(4), 371.